Resurrection Health Care®
For All of You, All of Your Life

CASE STUDY

Cavity from Removal of Infected Arteriovenous Graft Closed Quickly, Painlessly Using New Dressing*

Andrew M. Gorchynsky MD, CWS, FACS | Saint Joseph's Medical Center Resurrection Health Care | 2900 N. Lake Shore Drive | Chicago, IL 60657 USA



PROBLEM/GOAL

A 74-year-old male dialysis patient developed a draining infection in an old clotted A-V graft very close to his active left upper arm graft/fistula dialysis site. He no longer had viable graft/fistula sites in his right arm. Antibiotics were unsuccessful at resolving the infection, so two surgical incisions were made – one at the area of chronic drainage and another several inches distal to it – and the infected portion of the graft was bluntly dissected and carefully removed.

In OR: Day 0

In OR: Day 0

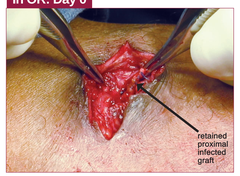

Scars from previous surgical procedures complicated the process. In order not to compromise the current functioning graft at the antecubital fossa, the proximal infected remnant of the graft was oversewn and left in place. The large cavity was then copiously irrigated with normal saline to confirm hemostasis.

This case study was unsponsored.
Ferris Mfg. Corp. contributed to
this poster presentation.

*PolyMem® Wic® Silver® Rope and Shapes by PolyMem® Silver Dressings are made by Ferris Mfg. Corp., Burr Ridge, IL 60527 USA• 800/POLYMEM

RATIONALE/MATERIALS

The proximal retained graft remnant was involved in the infection, but complete excision was not done in order to avoid damaging the adjacent functioning A-V graft/fistula. The distal retained graft portion was very susceptible to infection, which would threaten what was perhaps the patient's final dialysis access point. The patient did not have the means to come for follow-up more than twice a week. Conventional packing materials do not have the wicking properties needed to handle copious exudate for more than one or two days and have no special therapeutic properties. Silver polymeric membrane rope cavity filler* is antimicrobial, wicks drainage out of the wound bed, can be left in place for up to a week at a time, continuously cleanses the wound bed and inhibits the nociceptor response, which often results in dramatic pain relief. It is also very easy to insert and remove.

OBJECTIVES

1. Discuss the common problems associated with conventional methods of filling tunneling wounds.
2. Note that the silver polymeric membrane rope cavity filler decreased pain and inflammation. It slid easily into the tunnels, and removal was completely atraumatic as well. The patient reported "0" pain!
3. Consider the advantages of using a dressing that can continuously cleanse a tunneling wound.
4. Recognize the role the moisture-balancing qualities of the silver polymeric membrane rope cavity filler played in promoting rapid formation of granulation tissue.

METHODOLOGY

Silver polymeric membrane rope cavity filler was inserted at surgery. Two cut pieces of this unique rope cavity filler, placed side-by-side in the large cavity, extended from one incision to the other. Two more pieces (from the same package) extended into the clean transected area distal to the second incision. Initially the entire area was covered with a silver oval bordered polymeric membrane dressing. The bordered dressing was abandoned after only one day in favor of plain gauze, which could easily be replaced when it became saturated by the copious drainage pulled out of the wound by the polymeric membrane rope cavity filler. Stretch gauze, applied gently to avoid pressure on the active dialysis access point, held the gauze in place. The patient replaced the gauze as it became saturated. The rope was replaced whenever the patient was able to come for follow-up: every 3 – 7 days. Since the rope continuously cleanses wounds, no additional wound cleansing was done at dressing changes. The use of systemic antibiotics was avoided.

RESULTS

The silver polymeric membrane rope cavity filler effectively cleared the infection as it pulled the exudate from the originally infected superior area of the wound through the tunnel and out the inferior incision. Even with the retained graft foreign body, this at-risk patient did not require systemic antibiotics. The rope increased in size as it absorbed exudate, but not with enough pressure to prevent wound contraction, which took place rapidly. The patient experienced absolutely no wound pain, even during rope dressing removal and insertion. Granulation tissue was visible at the wound openings at the first dressing change. After 3½ weeks, the remaining cavity was so narrow that the rope dressing was discontinued, allowing the cavity to seal shut. The two incision sites closed two weeks later.

CONCLUSION

The new silver polymeric membrane rope cavity filler is an elegant and highly cost effective solution to the age-old problem of keeping cavity wounds appropriately moist and infection-free as they heal. The rope cavity filler wicked away excess wound drainage, allowing rapid healing and clearing of the infection. It is very easy to insert and remove. Patient comfort was outstanding, both when the rope was in place and at dressing changes. The fact that the dressings continuously cleansed the cavity may have contributed to the quick healing, because only minimal disruption of the newly formed granulation tissue took place at dressing changes. The initially infected cavity wound healed despite the presence of a retained portion of infected A-V graft material.

BIBLIOGRAPHY

1. Fluhr JW, Gloor M, Lehmann L, Lazzerini S, Distante F, Berardesca E. Glycerol accelerates recovery of barrier function in vivo. Acta Derm Venereol. 1999;79:418-421.
2. Clay CS, Chen, WYJ. Wound pain: the need for a more understanding approach. Journal of Wound Care. 2005;14:4,181-184.
3. Burd A, Kwok CH, Hung SC, Chan HS, Gu H, Lam WK, Huang L. A comparative study of the cytotoxicity of silver-based dressings in monolayer cell, tissue explant, and animal models. Wound Repair and Regeneration 2007;15:94-104.
4. Fleck, CA. Managing wound pain: today and in the future. Advances in Skin and Wound Care 2007;20:3,138-145.
5. Kim Y, Lee S, Hong S, Lee H, Kim E. The effects of polymem on the wound healing. J Korean Soc Plast Reconstr Surg 1999;109:1165-1172.
6. Togo T, Alderton JM, Bi GQ and Steinhardt RA. The mechanism of facilitated cell membrane resealing. Journal of Cell Science 1999;112(5)719-731.
7. Beitz AJ, Newman A, Kahn AR, Ruggles T, Eikmeier L. A polymeric membrane dressing with antinociceptive properties: analysis with a rodent model of stab wound secondary hyperalgesia. J Pain. 2004 Feb;5(1):38-47.
8. European Wound Management Association (EWMA). Position Document: Pain at wound dressing changes. London:MEP Ltd, 2002.
9. Middleton C. Understanding the physiological effects of unrelieved pain. Nursing Times. September 16, 2003; 99(37):28-31.
10. Sessions RC. Examining the evidence for a drug-free dressing's ability to decrease wound pain. Presented at 23rd Clinical Symposium on Advances in Skin and Wound Care. Poster #136, Oct 27 - 30, 2008. Las Vegas, NV.

In OR: Day 0

28 NOV 2008 Two cut pieces of silver polymeric membrane rope were inserted side-by-side in the 2.5 cm wide fistula and in the 2.5 cm wide tunnel distal to the second incision. Total length was ~8 cm.

In OR: Day 0 Active A-V fistula

28 NOV 2008 A bordered silver polymeric oval dressing was placed over the rope cavity filler in the surgical suite. Copious exudate necessitated frequent changes, so gauze was soon used instead.

Post Op Day 5

3 DEC 2008 The wound was continuously cleansed by the rope. No antibiotics were needed to prevent the retained graft portion from becoming re-infected (a big plus for a dialysis patient!).

Post Op Day 10

8 DEC 2008 The pieces of rope cavity filler were consistently saturated with exudate at twice-weekly dressing changes. At first they were slough-filled, but the wound beds stayed clean.

Post Op Day 13

11 DEC 2008 When the tunnels were clean and granulating, the dressings were inserted in both directions from the distal wound, avoiding the superior-most area so that it could close.

Post Op Day 17

15 DEC 2008 The superior end of the fistula closed as anticipated, decreasing concern for the nearby active A-V fistula. Only one layer of the rope dressing was now needed to fill the tunnels.

Post Op Day 20

18 DEC 2008 The two granulating tunnels were now barely wide enough for a single layer of silver polymeric membrane rope. Insertion into the narrow tunnels remained easy and pain-free.

Post Op Day 24

22 DEC 2008 Although the rope fit tightly in the narrow spaces when saturated, it slid out of the wound easily and atraumatically. Tissue did not have any tendency to grow into the dressing.

Post Op Day 31

29 DEC 2008 The tunnels were very narrow, clean and fully granulating, so the rope was discontinued. A pressure dressing could not be used due to the proximity of the active A-V fistula site.

Post Op Day 48

15 JAN 2009 The wound fully closed on 11 January. It remains closed without infection in the retained portion of graft. The active A-V fistula continues to serve the patient well.

Presented at: 8th Annual American Professional Wound Care Association • Poster #9
April 2 - 5, 2009 • Philadelphia, PA USA